

Definitive Treatment of Neurological Decompression Sickness in a Resource Limited Location

Matthew J. Petruso; Samuel M. Philbrick

BACKGROUND: While Fairbanks, AK, USA, is a remote location with significant constraints on medical resources and specialty care, a small U.S. Air Force clinic was able to provide a pilot with definitive care for neurological decompression sickness.

CASE REPORT: A 31-yr-old female patient presented to her flight surgeon in Anchorage, AK, USA, with migrating polyarthropathy and headaches 48 h after a flight which included planned aircraft decompression for high altitude low opening (HALO) jump operations. In order to get definitive treatment in a hyperbaric chamber, the patient typically would have to be flown to Seattle, WA, USA. This transfer of care would cost the Air Force approximately \$150,000 and may have led to more complicated disease. Fortunately, Eielson Air Force Base (AFB) in Fairbanks had previously procured a Hyperlite hyperbaric chamber specifically for this situation. After consultation with a hyperbaric specialist, the team decided that the most appropriate course of action was to transfer her by car 6 h north from Anchorage to Fairbanks. On initiation of the Hart treatment table, she experienced immediate reduction in joint pain with a reversal of neurological symptoms.

DISCUSSION: This patient's care could not have been done without the procurement of a hyperbaric chamber. This case demonstrates the utility and necessity for these capabilities at more facilities that manage significant flying operations. Military bases should ensure that hyperbaric treatment capabilities are available within a close proximity.

KEYWORDS: decompression sickness, neurological DCS, HALO jump, resource limited environment.

Petruso MJ, Philbrick SM. *Definitive treatment of neurological decompression sickness in a resource limited location. Aerosp Med Hum Perform.* 2021; 92(1):47–49.

Decompression sickness (DCS) is a well-described illness in the aeromedical community. However, in today's safety optimized operational environment, some flight surgeons complete their tour of duty without seeing a single case. Rapid diagnosis and treatment is imperative in preventing progression to severe and irreversible neurological sequelae.⁶ This case study highlights the value of hyperbaric capabilities in resource-limited environments in which flying operations occur.

CASE REPORT

A 31-yr-old female C-17 pilot with no significant past medical history underwent a controlled aircraft decompression from 9000 ft to 24,500 ft (2743 to 7468 m) in support of high-altitude low opening (HALO) jump operations. The patient prebreathed 100% oxygen for 30 min prior to depressurization, which has been found to decrease risk of DCS in hypobaric chamber training studies.⁵ She did not experience any symptoms during the flight, but 2 h after landing, she experienced a mild headache

and 2/10 right hip pain. She initially attributed the pain to being sore after a workout and did not immediately seek medical care. The following day, she developed mild left and right sacroiliac joint pain and the headache persisted. While pilots are trained to recognize symptoms of DCS, symptoms were subjectively mild and initially written off as being caused by exercise.

The patient presented to the local flight surgeon in Anchorage, AK, 48 h after the flight. Pain had migrated from her hip to her low back and right knee. A head-to-toe neurological examination was performed and found to be within normal limits. The hyperbaric medicine consultation service at Joint Base San Antonio was contacted and the senior consultant determined

From the 354 Medical Operations Squadron, U.S. Air Force, Eielson AFB, and the 673 Medical Group, U.S. Air Force, Joint Base Elmendorf-Richardson, AK, USA.

This manuscript was received for review in June 2020. It was accepted for publication in October 2020.

Address correspondence to: Matthew J. Petruso, D.O., Flight Surgeon, Flight Medicine, U.S. Air Force Medical Service, 2640 Central Ave., Eielson AFB, AK 99702, USA; petrusomatt@gmail.com.

Reprint & Copyright © by the Aerospace Medical Association, Alexandria, VA.

DOI: <https://doi.org/10.3357/AMHP.5701.2021>

that given the patient's presentation with migrating polyarthralgia, DCS needed to be treated. Moreover, the presence of headache (despite its mild and intermittent character) made neurological DCS the presumptive diagnosis. She was placed on 100% oxygen in the clinic and oral hydration was encouraged.^{4,7}

The patient needed hyperbaric treatment, but Joint Base Elmendorf-Richardson (JBER) does not have a hyperbaric chamber and there was no chamber available in the greater Anchorage municipality. The course of action articulated in DCS contingency plans was to fly patients to Seattle, WA, USA, for treatment, which the treating flight surgeon and hyperbaric medicine consultant deemed likely to complicate the patient's condition and impose undue expense and operational burden on JBER. Both commercial and military flights to Seattle were considered for definitive care. However, being in a remote location significantly limits options and increases time to treatment. The treatment team weighed the risks and benefits of sending the patient to Eielson Air Force Base (AFB) in Fairbanks, AK, USA, discussed the situation with the patient, and arranged to have the patient driven 6 h from Anchorage to Fairbanks in the company of a non-medical attendant. Such a long drive was counterintuitively the fastest option to initiate needed treatment; time to treatment with coordination of air transport was estimated to be another 24 h. It also mitigated the risk of decreased cabin pressures that could be experienced during a flight to Seattle and the costs of generating an air evacuation mission, estimated at \$150,000 USD. While early treatment of disease is generally considered best practice, multiple studies have shown favorable outcomes with treatment up to 14 d post-injury.³

The patient was transferred to Fairbanks via a personally owned vehicle (POV). Prior to departure, the patient was briefly placed on supplemental oxygen in accordance with the UHMS adjunct therapy guidelines (class 1 recommendation).⁸ However, logistical and safety concerns of bringing multiple oxygen tanks in a POV on a bumpy highway were raised and a team decision was made not to continue supplemental oxygen during the drive. She arrived at Eielson AFB at 02:30 for hyperbaric treatment. On presentation, she stated 3/10 right knee, right hip, and right lower back pain. A complete physical exam was repeated and she was found to have a markedly positive sharpened Romberg test with immediate falling to the left with eyes closed. This test was repeatable and she was stable with eyes open.

After consultation with the hyperbaric specialist, the Hart/Kindwall Monoplace Treatment Table was recommended. The decision was made for multiple reasons. Mechanical constraints of the Hyperlite made the air breaks of Navy Treatment Table 6 logistically difficult; the Hart table is shorter in duration (150 min vs. 285 min) and retrospective evidence suggests similar efficacy to Navy Treatment Table 6 for mild to moderate DCS.¹

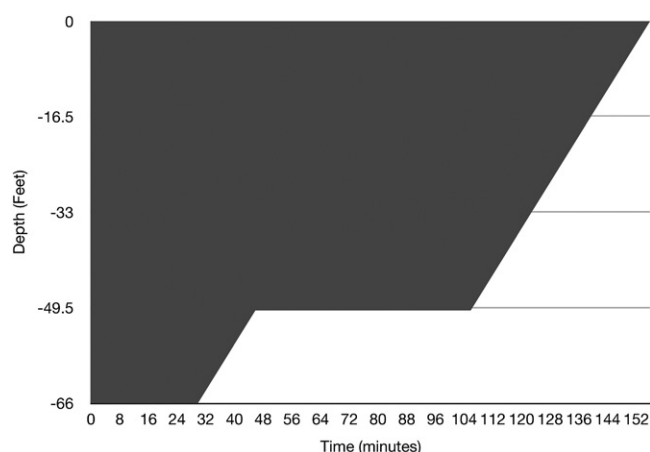


Fig. 1. A graphical representation of the Hart-Kindwall Treatment Table.

Prior to recompression, she was pretreated with two sprays of oxymetazoline per nostril (0.062 mg per nostril) to mitigate the risk of tympanic membrane rupture. After demonstrating successful Valsalva on otoscopic exam, she was positioned in the chamber and initiated on the Hart treatment table (See Fig. 1). Stages were as follows:

- Dive to 66 ft (20 m) in 12 min;
- Remain at 66 ft for 30 min;
- Climb to 50 ft (15 m) at a rate of $1 \text{ ft} \cdot \text{min}^{-1}$ ($0.30 \text{ m} \cdot \text{min}^{-1}$);
- Remain at 50 ft for 1 h; and
- Climb to 0 ft at a rate of $1 \text{ ft} \cdot \text{min}^{-1}$.

There were no complications during the procedure and the patient's only complaint was occasionally feeling overheated, which was mitigated by venting the chamber. Oxygen percentage within the chamber ranged from 20.5 to 21.9%, with an average of 21.2% (see Table I). Measurements were taken approximately every 10 min with more frequent measurements taken during descent and ascent. Variations from the Hart treatment table were negligible.

During treatment, the patient reported improving symptoms. After 10 min at 66 ft, the patient noted slight decrease of pain globally and by 25 min at 66 ft, she reported hip pain at almost complete resolution, with continuing decrease of knee and back pain. She reported knee pain as negligible at 75 min of treatment. Upon completion of the 165-min treatment, the patient subjectively reported complete resolution of right hip pain and significant improvement of right knee pain. Back pain was notably difficult to assess; the patient stated her back felt sore; however, she attributed this to lying on a hard surface for an extended period of time. A new set of vitals were performed as well as a physical exam. Vitals were all within normal limits and a notable resolution of the abnormal sharpened Romberg

Table I. Measured Percentage of Oxygen at Various Points During Treatment.

	MINUTES													
	5	9	13	15	26	35	50	63	72	85	95	122	135	148
% O ₂	20.9	21.3	20.5	21.3	21.9	20.9	20.3	21.4	21.3	21.4	20.9	21.6	21.5	21.3

was observed. Thus, resolution of DCS was achieved and the patient returned to her home base the following day by POV.

A return to flying status exam was performed by her flight surgeon less than 2 wk later. The only residual symptom she admitted was having a single, mild headache 1 wk after treatment that quickly resolved before she could seek medical attention. She admitted no pain and her physical exam was within normal conditions. The patient was subsequently returned to flying status and has required no further care for DCS for a full year after her illness.

DISCUSSION

DCS can still present in the aviation community even in today's safety-optimized environment while adhering to best practice guidelines. While attempts have been made to determine individual susceptibility based on anthropometric and physiological variables, such as age and gender differences, no conclusive studies have found significant predictive factors.^{9,10} Recently, it has been hypothesized that physical activities performed at altitude can contribute to development of DCS,² but the patient in this case was not performing strenuous activity while controlling the aircraft.

This case study clearly demonstrates a critical, time-sensitive need in aviation and diving military communities. While many military treatment facilities in the contiguous United States have access to large civilian institutions with hyperbaric capabilities, many base clinics operate in resource limited environments and communities without large tertiary medical centers. It is paramount to have the discussion of what hyperbaric resources are available in remote locations. A relatively small investment in a portable medical device saved the military a large sum of money and, more importantly, saved a patient from what could have been severe and long-term neurological sequelae. This case justifies the purchase of a small portable unit like the Hyperlite and further validates the sustainment of teleconsult services like the hyperbaric medicine consultation service that provided critical counsel to JBER and Eielson AFB physicians. With respect to clinical medicine, the case highlights the importance of keeping an appropriately high index of suspicion for DCS in aviators and divers, and underlines the need for all flight surgeons and General Medical Officer physicians to consider alternatives to pre-established courses of action in order to meet their patients' needs.

ACKNOWLEDGMENTS

The authors wish to thank Lt. Col. Matthew Ramage for supervision of treatment.

This paper reflects the views only of the authors and does not reflect the view of the 354 MDG, 673 MDG, or of the U.S. Air Force.

One of the authors submitted a poster abstract for the same case accepted by AsMA for the 2020 annual meeting for presentation. This case was not yet presented at AsMA due to the COVID-19 pandemic. However, this is the only written case report submitted for publication to date.

Financial Disclosure Statement: The Hyperlite Chamber is made by Survitec Group. The authors have no business relations or stock holdings in Survitec and have no financial incentives associated with the publication of this case report. The authors have no competing interests to declare.

Authors and affiliations: Matthew J. Petruso, D.O., 354 Medical Operations Squadron, Eielson AFB, AK, USA, and Samuel M. Philbrick, M.D., 673 Medical Group, Joint Base Elmendorf-Richardson, AK, USA.

REFERENCES

1. Cianci P, Slade JB. Delayed treatment of decompression sickness with short, no-air-break tables: review of 140 cases. *Aviat Space Environ Med.* 2006; 77(10):1003–1008.
2. Ercan E, Demir AE, Sabaner E, Toklu AS. Incidence of decompression sickness in hypobaric hypoxia training. *Undersea Hyperb Med.* 2020; 47(2):203–210.
3. Mitchell SJ, Doolette DJ, Wachholz CJ, Vann RD, editors. Management of mild or marginal decompression illness in remote locations. Durham (NC, USA): Divers Alert Network; 2005.
4. Moon RE, editor. Adjunctive therapy for decompression illness. Kensington (MD, USA): Undersea and Hyperbaric Medical Society; 2003.
5. Rice GM, Vacchiano CA, Moore JL Jr, Anderson DW. Incidence of decompression sickness in hypoxia training with and without 30-min O₂ prebreathe. *Aviat Space Environ Med.* 2003; 74(1):56–61.
6. Siewiera J, Szałański P, Tomaszewski D, Kot J. High-altitude decompression sickness treated with hyperbaric therapy and extracorporeal oxygenation. *Aerosp Med Hum Perform.* 2020; 91(2):106–109.
7. Undersea and Hyperbaric Medical Society. Adjunctive therapy for decompression illness (DCI): summary of Undersea and Hyperbaric Medical Society Guidelines. UHMS; 2002. [Accessed Sept. 2020]. Available from: <https://www.uhms.org/publications/online-store/report-of-the-decompression-illness-adjunctive-therapy-committee-of-the-undersea-and-hyperbaric-medical-society.html>.
8. Undersea and Hyperbaric Medical Society. Best practice guidelines: prevention and treatment of decompression sickness and arterial gas embolism. UMHS; 2011. [Accessed Sept. 2020]. Available from: https://www.uhms.org/images/DCS-AGE-Committee/dcsandage_prevandmgt_uhms-fi.pdf.
9. Webb JT, Kannan N, Pilmanis AA. Gender not a factor for altitude decompression sickness risk. *Aviat Space Environ Med.* 2003; 74(1):2–10.
10. Webb JT, Pilmanis AA, Balldin UI, Fischer JR. Altitude decompression sickness susceptibility: influence of anthropometric and physiologic variables. *Aviat Space Environ Med.* 2005; 76(6):547–551.