

## You're the Flight Surgeon

This article was prepared by Elizabeth A. Casstevens, M.D., M.P.H., M.S.

You are the flight surgeon working in the emergency department at an overseas operational base. Approximately 6 h into your shift, a call comes in over the radio that a pilot declared an in-flight emergency for acute abdominal pain and is being transported via the flight medicine ambulance crew to your emergency room. The patient is a 31-yr-old male F-16 pilot complaining of acute onset right lower quadrant (RLQ) abdominal pain with nausea and vomiting. Upon arrival, the medics report his vitals as blood pressure 147/83, respiratory rate 20, pulse 123, and pulse oximetry ( $S_pO_2$ ) 98% on room air. He was flying a Basic Fighter Maneuver profile and stated the pain was sharp and started suddenly while flying straight and level under 1 G after having pulled approximately 6 G sustained in a turn. He declared an in-flight emergency and, despite the pain, he was able to return to base and land the aircraft. The ambulance crew met the pilot at the aircraft, assisted him out of the cockpit due to his worsening abdominal pain, and transported him to the emergency department. The pilot had one episode of nonbloody, nonbilious emesis en route in the ambulance. His pain has worsened; he is now clutching his lower right side/pelvis area, is writhing in pain yelling, and is asking for pain medication. He denies any known drug allergies. He appears in obvious pain but nontoxic; repeat vitals are similar to above and aural temperature is 98.6°F.

### 1. Given the information above, what is your next step?

- A. Administer morphine 10 mg intravenous (IV).
- B. Assess his airway, breathing, and circulation (ABCs) and perform a focused physical exam.
- C. Send him for an abdominal computed tomography (CT) study.
- D. Draw a "rainbow" to assess for any lab abnormalities.

### ANSWER/DISCUSSION

**1. B.** Assess ABCs and perform a focused physical exam. As with any acute presentation of a patient in distress, it is important to first and quickly assess the pilot's "ABCs." In this case, you note the pilot's airway is patent as evidenced by his unhampered speech, his breathing is tachypneic although effective based on his  $S_pO_2$ , and you check his circulation via peripheral pulses, which are strong but reflect tachycardia. You also check for other disability ("D") by exposing ("E") the patient fully. You do not see any obvious injuries. You order a peripheral IV

line with simultaneous "rainbow" lab draw (each color tube top), including a complete blood count, complete metabolic panel, hepatic enzymes, amylase, lipase, magnesium, phosphorous, and erythrocyte sedimentation rate and start normal saline at maintenance fluid rate.

Now that you have determined the patient is stable, you give him morphine 10 mg IV and perform a focused physical exam. Although the patient is still in pain, it is better controlled and he is able to give you his past medical and surgical history, which is unremarkable (no significant illnesses or injuries and no surgeries), and additional details about his day up until the pain onset. The pilot tells you he slept well and ate his usual breakfast at home (eggs and cereal); approximately 1 h later, he experienced a mild bout of nausea with some RLQ "discomfort," but no vomiting. The nausea spontaneously resolved and he felt well enough to fly. He denies chest pain, shortness of breath, prior episodes of abdominal pain, testicular pain or swelling, hematuria, hematochezia, or any neurological symptoms. He also denies a history of flank pain, renal stones, urinary urgency, frequency, dysuria, or obstruction. He has no history of hypertension, urinary tract infections, frequent fevers, malaise, or previous abdominal pain and no noted subtle decline in general health or cognition. He denies any unapproved food or water sources. He has an unremarkable aeromedical history, with no ejections, decompression sickness, or other mishaps. While performing your history and physical exam, you consider some of the causes of adult abdominal pain.

### 2. What are some life-threatening causes of adult abdominal pain?

- A. Abdominal aortic aneurysm.
- B. Splenic rupture.
- C. Gastrointestinal tract perforation.
- D. All the above.

### ANSWER/DISCUSSION

**2. D.** All of the above are life-threatening causes of adult abdominal pain. Additional causes that must be considered include mesenteric ischemia, acute bowel obstruction, volvulus, and atypical presentation

DOI: <https://doi.org/10.3357/AMHP.4836.2017>

of myocardial infarction. In women, ectopic pregnancy and placental abruption must also be considered.

There are no findings on the pilot's head, neck, or cardiopulmonary exam; the abdominal exam is significant for direct and rebound tenderness to palpation located in the pilot's RLQ. Testicular exam is unremarkable. The pilot's pain seems to be decreasing and repeat vitals show he is normotensive with pulse now 98 and respiratory rate 14. His urine and blood lab results show no abnormalities. You are confident the pilot is stable enough to go to CT.

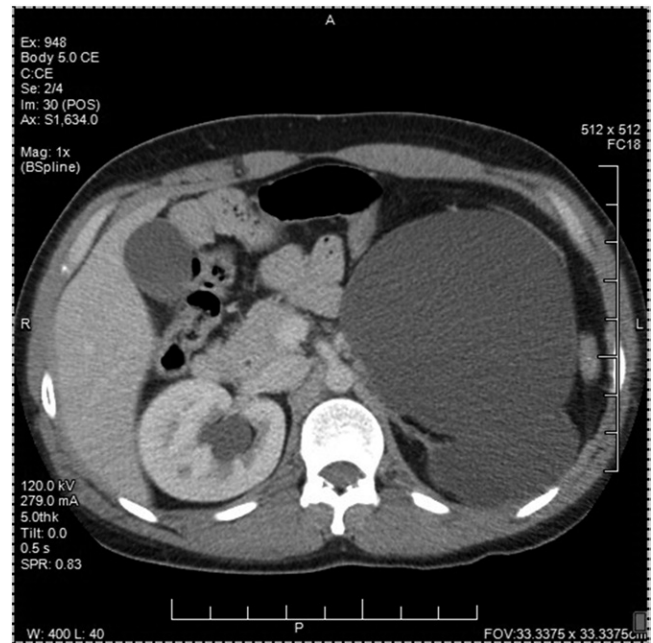
### 3. What diagnosis do you most likely expect to see on his CT?

- A. Incarcerated hernia.
- B. Acute appendicitis.
- C. Diverticular disease.
- D. Nephrolithiasis.

### ANSWER/DISCUSSION

**3. B. Acute appendicitis (AA).** After ruling out the above discussed life-threatening conditions, the most likely etiology of this pilot's pain is AA. AA is more common in males (1.4:1 male:female ratio) 10–19 yr old; however, the rate of AA has increased over 6% since 1993 in men 30–60 yr old.<sup>2</sup> Although the pilot's risk factors for an incarcerated hernia include male gender associated with a 25% lifetime risk of a groin hernia and recent increased intra-abdominal pressure (anti-G straining maneuver), an incarcerated hernia more commonly presents with groin pain or discomfort.<sup>5</sup> Additionally, in relatively thin patients, the clinical exam reveals a bulge at the site of the hernia. Diverticular disease more commonly presents in the left lower quadrant and in older patients. Nephrolithiasis usually presents with colicky pain, which could be similar to this pilot's pain, but hematuria is present in up to 90% of cases.<sup>4</sup>

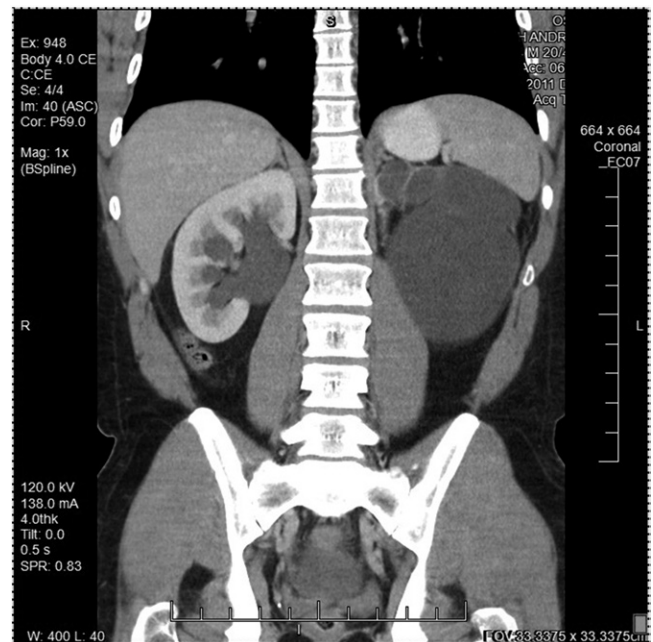
Your initial concern is AA, but due to the severity of his initial presenting pain, you also have concern for nephrolithiasis; after consultation with the general surgeon, you both decide to pursue the contrast study due to a higher suspicion for appendicitis after the clinical exam and the urinalysis results with no hematuria. The CT scan reveals a normal appendix, pancreas, and hepato-biliary system; however, it also shows complete, chronic left-sided ureteropelvic junction (UPJ) obstruction with cystic replacement of the left kidney and partial UPJ obstruction on the right (see Fig. 1, Fig. 2, and Fig. 3). The pilot's nausea has resolved and he did not have any more episodes of emesis, but he continued to have episodes of RLQ pain. Due to the abnormal CT findings and lack of appropriate specialty or surgical care at your location, you transfer the patient to a civilian hospital in the region, where he was admitted under the urology service for further observation. At the civilian hospital, he began to have testicular edema and continued intermittent abdominal pain; during one of these pain episodes, a bedside testicular ultrasound was done and the pilot was found to have right testicular torsion. He underwent testicular detorsion surgery and also required a bilateral orchiopexy to secure both testes. The surgery was successful and his abdominal pain resolved. The remainder of his hospital course was uneventful and he was discharged after obtaining a three-phase CT scan to assess the incidental finding of bilateral UPJ obstruction. The CT confirmed a left UPJ obstruction with severe



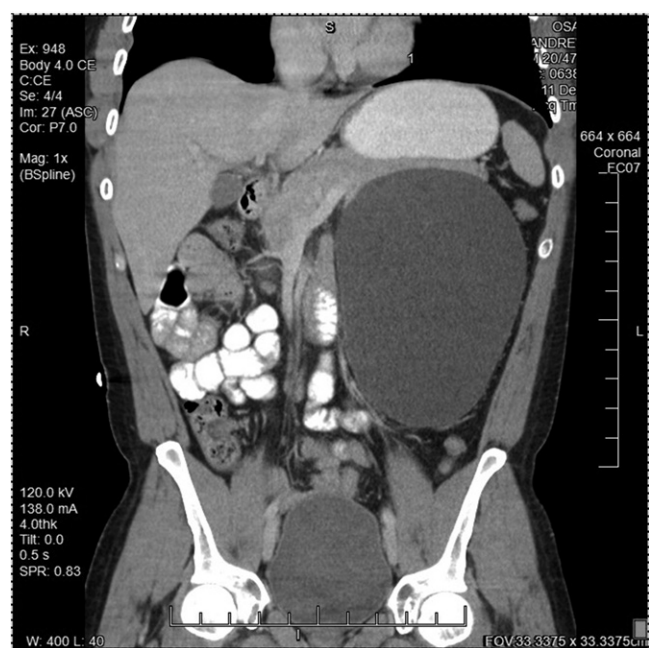
**Fig. 1.** Axial (transverse) view; complete, chronic left-sided UPJ obstruction with cystic replacement of the left kidney and partial UPJ obstruction on the right.

hydronephrosis and nearly absent left renal tissue and right UPJ stenosis with hydronephrosis.

The pilot continued urology follow-up for 6 wk, during which he underwent nuclear medicine renography, a dimercaptosuccinic acid scan, and a diethylenetriamine pentaacetic acid Lasix renogram to assess renal function. His right kidney had mild UPJ obstruction with no functional impairment, and his left kidney had severe hydronephrosis and was nonfunctioning. The local civilian urologist cleared



**Fig. 2.** Coronal view; complete, chronic left-sided UPJ obstruction with cystic replacement of the left kidney and partial UPJ obstruction on the right.



**Fig. 3.** Coronal view; complete, chronic left-sided UPJ obstruction with cystic replacement of the left kidney.

the pilot for flying duties, but recommended the pilot have a nonurgent prophylactic nephrectomy in the future to prevent a renal abscess.

Soon after being cleared by the overseas urologist, the pilot moved back to the United States and followed up with urology regarding the need for nephrectomy. He underwent a captopril renal function study, which verified normal right renal function without obstruction and a nonfunctioning left kidney. Urology estimated that since the hydronephrosis had never caused symptoms nor interfered with his duties, there was a <1% risk that his condition would cause an acute incapacitating event; hence, he did not require surgical intervention at that time. He requires annual lab testing including urinalysis and renal function testing to confirm normal, stable renal function and needs to remain asymptomatic. Should he become symptomatic or develop uncontrolled hypertension, then he should be reevaluated for a left nephrectomy.

#### 4. What do you recommend for this pilot's aeromedical disposition?

- A. Permanently disqualified, with no possibility of a waiver.
- B. Return to flight status after waiver approval, with no restriction on type of aircraft.
- C. Return to flight status after waiver approval, restricted to non-high-performance, multicrew aircraft only.

#### ANSWER/DISCUSSION

**4. B.** Return to flight status after waiver approval, with no restriction on type of aircraft. The primary concerns with congenital UPJ obstruction with hydronephrosis are the associated symptoms that could manifest, including abdominal pain, renal stones, hematuria, dysuria, infection, or fever. Pyelonephritis could lead to cortical scarring and

potentially compromise renal function. Less acute symptoms that could occur include malaise and subtle declines in overall health or cognition. Also, if this pilot's condition required frequent subspecialty follow-up, it would be incompatible with worldwide aviation duties.

This pilot's clinically quiescent bilateral UPJ obstruction with associated bilateral hydronephrosis was an incidental finding during a workup for unrelated pathology (the intermittent testicular torsion with the atypical presentation of RLQ abdominal pain without testicular pain). UPJ obstruction occurs in approximately 1 of 500 live births, affects males more than females, and is more common on the left side, with bilateral obstruction occurring in approximately 10% of cases.<sup>7</sup> His condition is most likely congenital; the cortical thinning and paper-thin parenchyma indicate a chronic obstruction. His left kidney is nonfunctioning due to the severe hydronephrosis. His right kidney has well-preserved function. With a normal functioning contralateral kidney, his urine output and serum creatinine are within normal limits. The Lasix renogram showed a nonpersistent obstruction of the right kidney. This condition likely occurred during fetal or infant life and then spontaneously resolved; although it resulted in dilatation of the right collecting system, it is not clinically significant at this time.

Because he is asymptomatic and does not have any residual left renal function to salvage, the benefits of a prophylactic left nephrectomy are likely minimal. Since surgical intervention is not needed at this time, continued observation is recommended, with immediate reevaluation of his condition if he becomes symptomatic or experiences any metabolic or hemodynamic sequelae. Although there is some concern that force on the left renal pedicle could result in bleeding, the pilot has never had symptoms and has maintained an active lifestyle, with proven physical performance under high-G conditions with no complications. As a result, his individual risk of this occurrence was determined to be low. However, to protect his solitary functioning kidney (whether from a condition such as what this pilot has or from a donor kidney transplant), you recommend he avoid extreme sports, contact sports, or any sport where he would undergo blunt force trauma (football, basketball, hockey, etc.).

Since this pilot's condition likely existed for many years, it is unlikely to progress or cause an acute incapacitating event. He is expected to remain stable under the stresses of the aviation environment and will not likely pose an increased risk to his health or safety, the safety of those around him, flight safety, or mission completion. Because he has only one functioning kidney, you counsel the pilot on renal precautions. You emphasize that because he essentially has a solitary kidney, he must be otherwise healthy to compensate for his condition. Specifically, essential management includes preventing dehydration and avoiding medications that may decrease his remaining renal function; if nonsteroidal anti-inflammatory drugs are needed, they should be taken at the lowest effective dose for the shortest duration possible. Because obstruction in a solitary kidney is a medical emergency and can very quickly deteriorate renal function, he should monitor for signs or symptoms of obstruction or nephrolithiasis, including flank pain, gross hematuria, or decreased urine output. He should continue to engage in healthy lifestyle choices. You preemptively recommend solitary kidney patients such as this pilot follow a low-sodium diet to prevent hypertension; one option is the Dietary Approaches to Stop Hypertension (or DASH) diet, which limits sodium intake to 2300 mg · d<sup>-1</sup>. Additionally, you counsel the pilot to



engage in regular exercise and maintain a healthy weight to reduce his risk of developing type 2 diabetes or hypertension, since these conditions jeopardize renal function.

Per the Air Force Waiver Guide, congenital UPJ obstruction with hydronephrosis is disqualifying for all flying classes, but is a waivable condition; Aeromedical Consult Service review is at the major command's discretion and is not mandatory.<sup>1</sup> The Aeromedical Consult Service reviewed this pilot's case and recommended a waiver. The pilot was subsequently granted an initial 3-yr waiver, pending no change in renal function status. You counsel the pilot of his personal responsibility to self-ground and report to you for immediate reassessment if he experiences any of the signs or symptoms discussed above.

The U.S. Navy's Manual of the Medical Department states that current or history of hydronephrosis is disqualifying.<sup>3</sup> Per the U.S. Navy Aeromedical Reference and Waiver Guide, this pilot's condition is disqualifying, but may be waived; it includes a section on congenital abnormalities of the kidneys, but does not specifically address hydronephrosis. However, the Guide does state that "waivers for conditions not specifically listed will be considered on case-by-case basis."<sup>8</sup>

U.S. Army Regulation 40-501 states that current or history of hydronephrosis is disqualifying.<sup>9</sup> The U.S. Army's Flight Surgeon's Checklists has a section on cystic and congenital abnormalities of the kidney, but does not specifically mention hydronephrosis. However, it does state that a waiver is possible in most cases if the flyer is asymptomatic and has adequate renal function.<sup>10</sup>

The Federal Aviation Administration (FAA) Guide for Aviation Medical Examiners addresses hydronephrosis, but only in the context of impaired renal function, which requires FAA decision. Since this pilot's renal function is within normal limits, he does not require a waiver, and the local aviation medical examiner can issue the medical certificate.<sup>6</sup> Regarding his testicular torsion, he underwent definitive treatment (orchiopexy), is fully healed, and has remained asymptomatic, so this condition does not require an aeromedical waiver for any of the military services nor for the FAA.

**Casstevens EA. You're the flight surgeon: an unexpected twist. *Aerosp Med Hum Perform*. 2017; 88(9):884–887.**

## ACKNOWLEDGMENTS

The author would like to thank Dr. (Maj.) Ellen Im, staff nephrologist, and Dr. (Maj.) Toby Lees, staff urologist, Wright-Patterson Medical Center,

Wright-Patterson AFB, OH, for their suggestions and professional review of this article. The views expressed in this article are those of the author and do not necessarily reflect the official policy or position of the Air Force, the Department of Defense, or the U.S. Government.

## REFERENCES

1. Ali TY, Van Syoc D. Congenital urinary anomalies (Feb 14). In: Air Force waiver guide. Wright-Patterson AFB (OH): U.S. Air Force School of Aerospace Medicine; 2016:233–238. [Accessed 1 Dec. 2016]. Available from <http://www.wpafb.af.mil/afri/711hpw/USAFSAM>.
2. Buckius MT, McGrath B, Monk J, Grim R, Bell T, Ahuja V. Changing epidemiology of acute appendicitis in the United States: study period 1993-2008. *J Surg Res*. 2012; 175(2):185–190.
3. Bureau of Medicine and Surgery. Article 15-47. Urinary system. In: Manual of the Medical Department. Washington (DC): Department of the Navy; 2016. NAVMED P-117. [Accessed 1 Dec. 2016]. Available from <http://www.med.navy.mil/directives/Pages/NAVMEDP-MANMED.aspx>.
4. Elton TJ, Roth CS, Berquist TH, Silverstein MD. A clinical prediction rule for the diagnosis of ureteral calculi in emergency departments. *J Gen Intern Med*. 1993; 8(2):57–62.
5. Everhart JE, editor. The burden of digestive diseases in the United States. Washington (DC): U.S. Department of Health and Human Services, National Institutes of Health, National Institute of Diabetes and Digestive and Kidney Diseases; 2008. NIH Publication No. 09-6443.
6. Federal Aviation Administration. Item 41. G-U system. Urinary systems. Guide for aviation medical examiners. Washington (DC): Federal Aviation Administration; 2016:118. [Accessed 1 Dec. 2016]. Available from [https://www.faa.gov/about/office\\_org/headquarters\\_offices/avsoffices/aam/ame/guide/media/guide.pdf](https://www.faa.gov/about/office_org/headquarters_offices/avsoffices/aam/ame/guide/media/guide.pdf).
7. Koff SA, Mutabagani KH. Anomalies of the kidney. In: Gillenwater JY, Grayhack JT, Howards SS, Mitchell ME, editors. Adult and pediatric urology, 4th ed. Philadelphia (PA): Lippincott Williams and Wilkins; 2001:2129–2154.
8. Naval Aerospace Medical Institute. 16.1 Congenital abnormalities of the kidneys. In: U.S. Navy aeromedical reference and waiver guide. Pensacola (FL): Naval Aerospace Medical Institute; 2016. [Accessed 1 Dec. 2016]. Available from [http://www.med.navy.mil/sites/nmotc/nami/arwg/Documents/WaiverGuide/Complete\\_Waiver\\_Guide.pdf](http://www.med.navy.mil/sites/nmotc/nami/arwg/Documents/WaiverGuide/Complete_Waiver_Guide.pdf).
9. U.S. Army. 2-15. Urinary system. In: Standards of medical fitness. Washington (DC): Department of the Army; 2011. Army Regulation 40-501. [Accessed 1 Dec. 2016]. Available from <https://armypubs.army.mil/default.aspx>.
10. U.S. Army Aeromedical Activity. Cystic and congenital abnormalities of the kidney. In: Flight surgeon's aeromedical checklists. Aeromedical policy letters. Ft. Rucker (AL): U.S. Army Aeromedical Activity; 2014. [Accessed 1 Dec. 2016]. Available from [http://glwach.amedd.army.mil/victoryclinic/documents/Army\\_APLs\\_28may2014.pdf](http://glwach.amedd.army.mil/victoryclinic/documents/Army_APLs_28may2014.pdf).

This article was prepared by Daniel R. Hatcher, D.O., M.P.H.

You're the flight surgeon working your clinic when a 40-yr-old pilot you know well comes in for his annual flight physical. Throughout the appointment, you identify nothing concerning on his questionnaire or physical examination. Before you clear him for another year, you ask if there is anything else that he would like to discuss. He hesitantly responds that he had an incident that scared him a few nights before.

He was driving home with his wife after dinner when he experienced visual difficulties. He states that he lost visual acuity while driving and was seeing flashes of light in his visual fields. His symptoms were significant enough that he had to pull over and have his wife

DOI: <https://doi.org/10.3357/AMHP.4857.2017>

drive the rest of the way home. These symptoms persisted for about 40–50 min. He also admits that this is the second time that he has had such symptoms. The first time was about 2 wk ago.

**1. From your initial impression, which of the following should be lowest on your differential for this problem?**

- A. Retinal detachment.
- B. Migraine aura without headache.
- C. Occipital stroke/transient ischemic attack (TIA).
- D. Partial seizures.
- E. Acute angle-closure glaucoma.

**ANSWER/DISCUSSION**

**1. E.** Acute angle-closure glaucoma presents with decreasing visual acuity or colorful halos around lights, due to corneal edema, over a few hours and is accompanied by acute eye pain, headache, nausea, and/or vomiting.<sup>17,18</sup> Additionally, it presents with vascular congestion, conjunctival hyperemia, and ciliary flush.<sup>17,18</sup> This is usually a monocular phenomenon; however, there is an increased risk of glaucoma in the contralateral eye. Prompt evaluation of this phenomenon would reveal increased intraocular pressures (>30 mmHg), mid-dilated and sluggish pupil (4–6 mm), and a shallow anterior chamber when measured.<sup>17,18</sup> This is a medical emergency and needs prompt evaluation and treatment.<sup>17,18</sup> The pilot in question exhibited none of these symptoms. His history of relatively rapid onset of painless decrease in visual acuity with bright flashes of lights and symptoms lasting only 40–50 min is not consistent with acute ocular hypertension.

Retinal detachments can manifest with flashes of light associated with noticeable loss of visual acuity in large detachments.<sup>20,23</sup> The flashes of light have a sudden onset and progress as the retinal detachment progresses. This is accompanied by floaters due to debris and vitreous blood.<sup>20,23</sup> The flashes of light resolve spontaneously, but the loss of vision generally does not resolve without prompt interventions.<sup>21,23</sup> A thorough retinal evaluation with direct funduscopy and indirect ophthalmoscopy will be able to evaluate for this condition. Retinal detachments may progress if not treated.<sup>20,23</sup> Also, having a detachment in one eye is a risk factor for a subsequent ipsilateral detachment, but bilateral simultaneous detachments are exceedingly rare.<sup>20,23</sup>

Typical migraine aura without headache is a rare condition that presents itself in adults with classic migraine auras and occurs with or without cephalalgia.<sup>9</sup> The most common migraine auras are visual, sensory, and/or language symptoms. This is a diagnosis of exclusion, with diagnostic criteria established by the International Headache Society (IHS), including full reversibility of symptoms.<sup>8</sup>

A TIA can cause visual symptoms similar to those described. As the optic nerves transverse the length of the brain, there are numerous ways a vascular incident can affect vision. When a TIA occurs behind the optic chiasm, it produces visual symptoms that are homonymous. In addition, when the event affects the optic nerve anterior to the optic chiasm, symptoms are monocular. The symptoms that occur as a result of an occlusive vascular phenomenon in the occipital region are sudden onset and can include partial loss of vision, complete blindness, and visual hallucinations. TIA symptoms last less than

5 min and full stroke symptoms generally last days or can cause a permanent defect.

Partial seizures that affect the optic pathway can cause recurrent visual symptoms. Visual hallucinations from occipital seizures generally are characterized by a prototypical constellation of symptoms. These visual hallucinations are colored and circular, appearing over a few seconds and lasting a few minutes. The symptoms begin in the periphery of a hemifield of vision and often move across to the other side.<sup>15,16</sup> Partial seizures do not typically present in adults unless there is an accompanying brain lesion such as from a tumor, trauma, or vascular disease.<sup>2,14</sup>

On further evaluation, this pilot states that the visual disturbance began in the central vision and progressed to involve most of his visual field. From the onset of symptoms to maximum intensity, it progressed over about 10 min. He denies any persistent blind spots in his vision after the episode. A thorough review of systems is unrevealing for any further symptoms. He denies any recent headache and any history of migraines at a younger age and has no family history of migraines, vascular disease, or neurological conditions. He has no recent trauma. His risk for vascular disease is low as he has normal cholesterol and blood pressure, no diabetes, has never smoked, and has a benign family history. A thorough examination reveals a healthy 40-yr-old man who takes no medications. His vital signs are normal. A fundoscopic evaluation shows a normal retina and normal cup-to-disc ratio. The neurological examination is unrevealing for any cranial nerve pathology or other neurological signs. Cardiovascular examination reveals a regular heart rate and rhythm with normal S1 and S2 without murmurs or gallops; carotid examination is without bruits.

**2. Which of the following can distinguish the visual aura of migraine from those of structural brain lesions?**

- A. Absence of headache (acephalgia).
- B. Increasing frequency of visual aura.
- C. Persistent visual field defects.
- D. No past history of migraines.
- E. Duration of visual aura.

**ANSWER/DISCUSSION**

**2. C.** Persistent visual field defects. As migraine aura without headache is thought to follow the same pathophysiology as typical migraines, once the incident is resolved the patient should be completely symptom free and without any residual effects.<sup>9,22</sup> In contrast, any lesion along the visual pathway or occipital cortex has the potential to leave a permanent loss of visual fields.<sup>22</sup> Therefore, a fixed visual loss after an episode of visual symptoms should be concerning for a structural lesion.

In this patient, we see the absence of headache. While a headache is most commonly associated with migraine aura, about 1.2% of the population will experience migraine aura without headache.<sup>4,7</sup> Additionally, headache is not uncommon in patients with occipital seizures and occasionally occurs with TIAs/strokes.<sup>15,19</sup> The presence or absence of headache cannot be used to rule in or out a competing diagnosis;

therefore, in the presence of concerning visual symptoms, further evaluation of the patient is warranted to evaluate the possibility of cerebral vascular disease or seizure.

Progression in severity or frequency of headaches or aura symptoms is concerning for additional pathology and should prompt further investigation.<sup>22</sup> In the case of this pilot, he has no prior history of migraines. Therefore, the occurrence of these symptoms constitutes a progression in the frequency of his symptoms and warrants a more thorough workup. However, with the prevalence of migraines in the adult population of about 12%, using severity or frequency as a distinguishing criterion is inappropriate.<sup>9,12</sup>

The majority of patients who experience symptoms such as those described by this pilot have a history of migraines when they were younger.<sup>9</sup> Even if a patient has a prior or current history of migraines and then visual aura symptoms develop, this change in headache pattern and new aura should raise concerns regarding new pathology that is causing the new symptoms.<sup>22</sup> Imaging of the brain would be appropriate to ensure that no other concomitant pathology exists. This pilot has no history of migraines or trauma and has no risk factors for stroke, yet due to the new onset of symptoms, imaging was obtained to ensure no cortical lesions were present.

The IHS states that visual aura symptoms with migraines have an onset of between 5 and 20 min and a duration of less than 60 min.<sup>8</sup> However, a study and review of the literature by Shams and Plant showed that the duration of visual symptoms of cerebral lesions was between 20 and 30 min.<sup>22</sup> Additionally, the visual symptoms of seizure disorders usually last less than 5 min, but no more than 15 min without being considered status epilepticus.<sup>2,15</sup> Due to the significant overlap in the duration of symptoms, these cannot be reliably differentiated from migraines using symptom timing.<sup>22</sup>

In this pilot, magnetic resonance imaging studies of the brain and carotid arteries were obtained with and without contrast. These showed normal anatomy without concern for stroke or vascular disease. It was decided that his risk for developing *de novo* partial seizures at the age of 40 was exceedingly low. Additionally, the length and timing of his symptoms with a crescendo over 10 min and resolution in 40–50 min were not consistent with partial seizures, so an electroencephalogram was not pursued unless his symptoms continued to worsen.

### 3. What is your final diagnosis for this patient?

- A. Occipital TIA.
- B. Adult onset partial seizures.
- C. Migraine aura without headache.
- D. Bilateral branch retinal artery occlusions.

## ANSWER/DISCUSSION

**3. C. Migraine aura without headache.** During the workup of this pilot, he was found to have no risk factors for vascular disease and neuroimaging was unremarkable. As discussed above, there is little concern of adult onset partial seizures without a history of recent head trauma or cortical lesion (scar, tumor, etc.). If there was a concern for seizures, then an electroencephalogram could be considered in conjunction with the neurology consult. Retinal detachments were ruled out by retinal evaluation.

The final diagnosis in this case is one of exclusion. The diagnostic criteria put forth by the IHS take into account that other disease processes can cause the same visual symptoms and therefore express the importance of making sure that there is no other pathology present. The two most likely competing diagnoses with migraine aura without headache are stroke/TIA and partial seizures.<sup>9</sup> Each of these has unique diagnostic criteria, but the presenting symptoms can be overlapping.

According to the IHS, migraine aura “consists of visual and/or sensory and/or speech/language symptoms, but no motor weakness, and is characterized by gradual development [ $\geq 5$  min], duration of each symptom no longer than 1 hour ... and complete reversibility.”<sup>8</sup> Additionally, there needs to have been at least two attacks, the symptoms cannot be accounted for by other diagnoses, and TIA has been excluded.<sup>8</sup>

Migraine aura can present with a variety of neurological manifestations. The most common aura manifestations are visual symptoms and include flashes of light (photopsia), partial loss of vision (scotoma), hemianopsia, diplopia, blindness, and visual illusions/distortions of perception (metamorphopsia).<sup>4,7,9</sup> Less common neurological manifestations of migraine aura are symptoms of paresthesias, vertigo, amnesia, confusion, hemiparesis, hearing loss, or mood alterations.<sup>4,7–9</sup>

With 12% of the population reporting migraines, those experiencing aura symptoms at least occasionally with their migraines range from 15–32%.<sup>1,4,7</sup> The reported prevalence of migraine aura without headache has ranged from 37–58% of those with a history of migraine with aura.<sup>4,9,11,26</sup> Migraine aura without headache is most common in adults over the age of 50, but has been reported at all ages.<sup>4,9</sup> A study looking at aura patients by age found no difference in gender distribution (3:1 female to male), type of aura, or history of migraines, but did find that auras were associated with headaches less with older age of onset.<sup>10</sup>

## AEROMEDICAL DISPOSITION

According to the U.S. Air Force Medical Standards Directory\* and the Air Force Waiver Guide,<sup>24</sup> all headaches, except for occasional tension headaches, are disqualifying for flying duties. Waivers are considered on a case-by-case basis. Headaches that impair social, vocational, or academic performance, require the use of abortive medications other than over-the-counter or require a prescription prophylactic medication, or have any associated neurological symptoms are not considered waiverable. A waiver may be considered if there are less than three headaches per year and they do not have any of the above listed characteristics. Any headaches not meeting these requirements need to be reviewed by the Aeromedical Consult Service (ACS).<sup>24</sup> For the pilot in this case, he would be disqualified and would need to be reviewed by the ACS.

\* U.S. Air Force. Section I: neurologic USAF medical standards, L21. In: Medical standards directory; 2016:43. [Accessed 1 Dec. 2016]. Available from <https://kx2.afms.mil/kj/kx4/FlightMedicine%2FDocuments/Forms/ShowFolders.aspx?RootFolder=%2Fkj%2Fkx4%2FFlightMedicine%2FDocuments%2FMedical%20Standards%20Directory%20%28MSD%29&FolderCTID=0x0120004DEB19A0C597EF4794DF99094B5AD8FC&View=%7BF2BF56F2%2D1249%2D4387%2DBBD9%2DFF9D369D4FC0%7D> to those with access.

In the U.S. Army, migraines are considered disqualifying for flying duties.<sup>25</sup> The Army does not usually grant exceptions to policy in initial pilot training applicants for migraine headaches unless they have been symptom free for greater than 12 mo and are on no medications. For currently rated aviators, waivers are considered on a case-by-case basis and are usually not recommended if there are neurological or visual symptoms that accompany the headache. Final determination for waiver is based on general performance, special senses affected, and the risk of recurrence. The required workup includes a neurology evaluation, detailed migraine history, brain imaging with computed tomography or magnetic resonance imaging, and an ophthalmology evaluation if the patient's symptoms include visual disturbances.<sup>25</sup> For the pilot in question, he would be disqualified from flying and would require a waiver or exception to policy to fly. While he is pain free, the disturbance of special symptoms in his vision is of particular concern.

In the U.S. Navy, any headache syndrome that interferes with normal function in the past 3 yr is disqualifying.<sup>3</sup> According to the U.S. Navy Aeromedical Reference and Waiver Guide, headaches are evaluated on the basis of their impact on general performance, the effects on special senses, and their risk of recurrence. Specifically listed as disqualifying are migraine headaches with aura and scotoma, headaches that prohibit the performance of activities, and those that have required treatment in an emergency department, hospital, or acute care clinic. Also disqualifying are neurological dysfunction other than nausea/vomiting or photophobia. Treatments other than simple analgesics or nonpharmacological methods are also disqualifying. Waivers may be considered after an evaluation by the Naval Aerospace Medical Institute Neurology Division and a review of the following factors: frequency of headaches (no more than three a year), occurrence during flight, predictability, severity, history of incapacitation, and treatment required (note that daily verapamil is the only acceptable prophylactic medication). Also considered is type of aircraft and duties, experience and status (new applicant vs. trained asset), and the underlying diagnosis and presentation.<sup>13</sup> As in the other services, the pilot in this case would be disqualified due to particular concern about the visual symptoms.

According to the Federal Aviation Administration (FAA) Guide for Aviation Medical Examiners, pilots with common migraines without neurological symptoms may be issued a certificate by the Aviation Medical Examiner (AME) if the condition meets the limited criteria according to the Conditions AMEs Can Issue (CACI) worksheet.<sup>6</sup> The criteria are that symptoms are considered mild and are controlled on approved medications (over-the-counter, noninjectable triptans, metoclopramide, or promethazine) with no more than one episode per month. The applicant cannot be taking any prophylactic agents for migraines or have had any in-patient treatments and no more than two out-patient clinical or urgent care visits to treat exacerbations during the previous year. Meeting these criteria, the AME can issue a certificate.<sup>5</sup> A pilot with migraines that present beyond these criteria will not be issued a certificate and must submit the examination to the FAA for a decision.<sup>6</sup> This pilot would not qualify for an FAA certificate to be issued from an AME at this point because he has visual symptoms that classify his migraines as ocular as listed on the CACI worksheet.

The pilot who presented to your office was disqualified from flying and his case was reviewed by the Air Force ACS. After performing

nonflying duties for 18 mo, he had one additional recurrence 3 mo after the first two. During this nonflying time, he received 1 mo of acupuncture for these symptoms, but other than this he had no other treatments. He reapplied for a waiver following this 18-mo period. After review of his case, he received a restricted pilot waiver where he was granted privileges to fly in multicrew aircraft. This waiver was granted based on the rarity of symptoms and the slow development of the visual auras when symptoms were present.

Overall, the diagnosis of migraine aura without headache should be considered disqualifying due to the symptoms, presentation, and special senses affected. These migraines may be considered for a waiver on an individual basis in all the flying communities in the United States. The diagnosis of migraine aura without headache is one of exclusion and every effort should be undertaken to investigate other competing diagnoses that could explain the presenting symptoms.

**Hatcher DR. *You're the flight surgeon: migraine aura without headaches*. *Aerosp Med Hum Perform*. 2017; 88(9):887–891.**

## ACKNOWLEDGMENTS

The author would like to thank Col. Roger Hesselbrock, neurology consultant, U.S. Air Force School of Aerospace Medicine, for his advice and professional review of this article. The views expressed in this article are those of the author and do not necessarily reflect the official policy or position of the Air Force, the Department of Defense, or the U.S. Government.

## REFERENCES

1. American Headache Society. Epidemiology and impact of headache and migraine. (n.d.) [Accessed 28 Nov. 2016]. Available from [https://americanheadachesociety.org/wp-content/uploads/2016/07/NAP\\_for\\_Web\\_-\\_Epidemiology\\_Impact\\_of\\_Headache\\_Migraine.pdf](https://americanheadachesociety.org/wp-content/uploads/2016/07/NAP_for_Web_-_Epidemiology_Impact_of_Headache_Migraine.pdf).
2. Banerjee PN, Filippi D, Allen Hauser W. The descriptive epidemiology of epilepsy—a review. *Epilepsy Res*. 2009; 85(1):31–45.
3. Bureau of Medicine and Surgery. Article 15-57. Neurological disorders. In: Manual of the Medical Department. Washington (DC): Department of the Navy; 2016. NAVMED P-117. [Accessed 1 Dec. 2016]. Available from <http://www.med.navy.mil/directives/Pages/NAVMEDP-MANMED.aspx>.
4. Evans RW. Case studies of uncommon and rare headache disorders. *Neurol Clin*. 2016; 34(3):631–650.
5. Federal Aviation Administration. CACI – migraine and chronic headache worksheet. In: Guide for aviation medical examiners. Washington (DC): Federal Aviation Administration; 2016. [Accessed 28 Nov. 2016]. Available from [https://www.faa.gov/about/office\\_org/headquarters\\_offices/avs/offices/aam/ame/guide/media/C-CACIMigraine.pdf](https://www.faa.gov/about/office_org/headquarters_offices/avs/offices/aam/ame/guide/media/C-CACIMigraine.pdf).
6. Federal Aviation Administration. Decision considerations – aerospace medical dispositions. Item 46. Neurologic – headaches. In: Guide for aviation medical examiners. Washington (DC): Federal Aviation Administration; 2016. [Accessed 28 Nov. 2016]. Available from [https://www.faa.gov/about/office\\_org/headquarters\\_offices/avs/offices/aam/ame/guide/app\\_process/exam\\_tech/item46/amd/ha/](https://www.faa.gov/about/office_org/headquarters_offices/avs/offices/aam/ame/guide/app_process/exam_tech/item46/amd/ha/).
7. He Y, Li Y, Nie Z. Typical aura without headache: a case report and review of the literature. *J Med Case Rep*. 2015; 9:40.
8. Headache Classification Committee of the International Headache Society. The International Classification of Headache Disorders, 3rd edition (beta version). *Cephalgia*. 2013; 33(9):629–808.
9. Kunkel RS. Migraine aura without headache: benign, but a diagnosis of exclusion. *Cleve Clin J Med*. 2005; 72(6):529–534.



10. Martins IP, Goucha T, Mares I, Antunes AF. Late onset and early onset aura: the same disorder. *J Headache Pain*. 2012; 13(3):243–245.
11. Mattsson P, Lundberg PO. Characteristics and prevalence of transient visual disturbances indicative of migraine visual aura. *Cephalalgia*. 1999; 19(5):479–484.
12. Merikangas KR. Contributions of epidemiology to our understanding of migraine. *Headache*. 2013; 53(2):230–246.
13. Naval Aerospace Medical Institute. 10.5 Headaches and migraines (15 Aug. 2015). In: U.S. Navy aeromedical reference and waiver guide. Pensacola (FL): Naval Aerospace Medical Institute; 2016. [Accessed 1 Dec. 2016]. Available from <http://www.med.navy.mil/sites/nmotc/nami/arwg/Pages/AeromedicalReferenceandWaiverGuide.aspx>.
14. Noe KH. Seizures: diagnosis and management in the outpatient setting. *Semin Neurol*. 2011; 31(1):54–64.
15. Panayiotopoulos CP. Elementary visual hallucinations, blindness, and headache in idiopathic occipital epilepsy: differentiation from migraine. *J Neurol Neurosurg Psychiatry*. 1999; 66(4):536–540.
16. Panayiotopoulos CP. Visual aura of migraine versus visual occipital lobe seizures. *Cephalalgia*. 2012; 32(8):654.
17. Pokhrel PK, Loftus SA. Ocular emergencies. *Am Fam Physician*. 2007; 76(6):829–836.
18. Prum BE, Herndon LW Jr, Moroi SE, Mansberger SL, Stein JD, et al. Primary Angle Closure Preferred Practice Pattern® guidelines. *Ophthalmology*. 2016; 123(1):P1–P40.
19. Raghunathan S, Richard B, Khanna P. Causes and clinical characteristics of headache in ischaemic stroke. *Prog Neurol Psychiatry*. 2008; 12(5): 21–23.
20. Rao RC, Shah GK. Rhegmatogenous retinal detachment. In: Yanoff M, Duker JS, editors. *Ophthalmology*, 4th ed. Philadelphia (PA): Elsevier Saunders; 2014:646–652.
21. Reid A, Baxley E, Stanek M, Newton W. Practice transformation in teaching settings: lessons from the I-3 PCMH collaborative. *Fam Med*. 2011; 43(7):487–494.
22. Shams PN, Plant GT. Migraine-like visual aura due to focal cerebral lesions: case series and review. *Surv Ophthalmol*. 2011; 56(2):135–161.
23. Sharma R, Brunette DD. *Ophthalmology*. In: Marx JA, Hockberger RS, Walls RM, editors. *Rosen's emergency medicine: concepts and clinical practice*, 8th ed. Philadelphia (PA): Elsevier Saunders; 2014:909–930.
24. Tontz R, Hesselbrock R, Van Syoc D. Headache (Jan 14). In: Air Force waiver guide. Wright-Patterson AFB (OH): U.S. Air Force School of Aerospace Medicine; 2016:379–388.
25. U.S. Army Aeromedical Activity. Migraine (ICD9 346.9). In: In: Flight surgeon's aeromedical checklists: aeromedical policy letters. Ft. Rucker (AL): U.S. Army Aeromedical Activity; 2014. [Accessed 1 Dec. 2016]. Available from [http://glwach.amedd.army.mil/victoryclinic/documents/Army\\_APLs\\_28may2014.pdf](http://glwach.amedd.army.mil/victoryclinic/documents/Army_APLs_28may2014.pdf).
26. Zieqler DK, Hassanein RS. Specific headache phenomena—their frequency and coincidence. *Cephalalgia*. 1989; 9(10, Suppl.)178–179.