

# Treatment and Monitoring of Central Serous Chorioretinopathy in Pilots

Ari Shinojima; Ryusaburo Mori; Kyoko Fujita; Mitsuko Yuzawa

- BACKGROUND:** Central serous chorioretinopathy (CSC), which has the characteristics of a serous retinal detachment (SRD) in the macular area, affects mostly men in the 30- to 50-yr age range. Some patients have persistent SRD, which may cause retinal thinning and photoreceptor impairment. CSC symptoms are gradual vision loss and/or metamorphopsia. Some commercial airline pilots are concerned about CSC symptoms, which can disqualify them from flying for months and can also reoccur. Thus, careful monitoring and treatment of CSC are critical for pilots, especially those with chronic or recurrent CSC. The Federal Aviation Administration requires uncorrected distant visual acuity in the better eye to be 20/200 or better, with correction to 20/20 or better employing lenses of no greater power than  $\pm 3.5$  diopters spherical equivalent. Multimodal imaging modalities such as spectral domain optical coherence tomography (SD-OCT) allow early detection of CSC noninvasively. Moreover, half-dose verteporfin photodynamic therapy (PDT) can cure CSC in the early stage.
- CASE REPORTS:** Five male Japanese commercial airline pilots with CSC are presented. Four of these five pilots had been disqualified from flying for several months, but after receiving half-dose PDT, they were ultimately able to resume flying commercial aircraft.
- DISCUSSION:** Half-dose PDT can rapidly reduce serous subretinal fluid in CSC eyes. Recurrent and/or chronic CSC is seen in clinical cases. Therefore, continuous observation by SD-OCT after half-dose PDT is essential, even if the patient's vision recovers. Early, i.e., before visual acuity decreases, treatment is highly recommended.
- KEYWORDS:** eye, metamorphopsia, photodynamic therapy, retinopathy, spectral domain optical coherence tomography, visual changes.

Shinojima A, Mori R, Fujita K, Yuzawa M. *Treatment and monitoring of central serous chorioretinopathy in pilots.* *Aerosp Med Hum Perform.* 2016; 87(12):1041–1044.

Central serous chorioretinopathy (CSC) is characterized by serous retinal detachment (SRD) in the macular area.<sup>5</sup> SRD results in the development of fluid leaks underneath the retina and the retina then takes on a ballooned up appearance due to the accumulation of this fluid. If SRD persists in CSC patients, retinal thinning and photoreceptor impairment may occur.<sup>10</sup> The symptoms of CSC are gradual vision loss and/or metamorphopsia, and, for pilots, the possibility of important symptoms such as dyschromatopsia, decrease in contrast sensitivity, and night vision impairment must be considered.<sup>2,11</sup> CSC affects mostly men 30–50 yr of age.

Nowadays, multimodal imaging modalities such as spectral domain optical coherence tomography (SD-OCT), which allows early detection of SRD noninvasively, are available. SD-OCT uses infra-red light waves to obtain cross-sectional pictures of the retina and choroid. Moreover, fluorescein angiography (FA) and indocyanine green angiography (ICGA) are used to diagnose CSC.

There are many reports related to CSC treatment, with laser photocoagulation formerly being the first choice for CSC. However, laser photocoagulation can potentially damage the surrounding healthy tissue and cause scotoma. Therefore, laser photocoagulation is not feasible for leakage points near the fovea or for diffuse leakage detected by FA.

We have reported more than 200 eyes with CSC undergoing half-dose verteporfin photodynamic therapy (PDT), which is an effective and safe method for treating CSC eyes with leakage near the fovea, such that photocoagulation is not

From Nihon University Hospital, Chiyoda-ku, Tokyo, Japan.

This manuscript was received for review in May 2016. It was accepted for publication in August 2016.

Address correspondence to: Ari Shinojima, M.D., Ph.D., Department of Visual Science, Division of Ophthalmology, Nihon University School of Medicine, Nihon University Hospital 1-6, Surugadai, Kanda, Chiyoda-ku, Tokyo 101-8309, Japan; ariearly7@gmail.com.

Reprint & Copyright © by the Aerospace Medical Association, Alexandria, VA.

DOI: 10.3357/AMHP.4671.2016

feasible, and/or obscure leakage detected by FA.<sup>3,4</sup> Half-dose PDT can cure CSC in the early stage. However, in Japan, PDT is performed mainly for age-related macular degeneration as this condition is covered by the Japanese National Health Insurance system. PDT has not as yet been approved as a treatment for CSC. We obtained institutional review board approval for using half-dose PDT on CSC patients from Surugadai Nihon University Hospital in 2008.

The CSC resolves and best corrected visual acuity (BCVA) reportedly improves significantly after PDT.<sup>3</sup> CSC symptoms, which can result in flight status disqualification for several months and may even recur, are a concern for active pilots. Thus, initial detection, treatment, and meticulous follow-up observation of CSC are critical in the aviation industry, especially for pilots with chronic or recurrent disease. We therefore introduce herein half-dose PDT for pilots with CSC.

## CASE REPORTS

The five Japanese commercial pilots studied herein were all men (age  $47.2 \pm 6.3$  yr; range 41–55 yr; **Table I**). All five had symptomatic CSC and underwent PDT using half the normal dose of verteporfin (Visudyne; Novartis AG, Bulach, Switzerland). All procedures adhered to the tenets of the Declaration of Helsinki. Written informed consent was obtained from all patients.

First, we gave the patient a drip and infused a  $3 \text{ mg} \cdot \text{m}^{-2}$  dose of verteporfin over 10 min. Next, after 15 min of verteporfin infusion, we applied a 689-nm laser treatment. Usually, we infuse  $6 \text{ mg} \cdot \text{m}^{-2}$  for age-related macular degeneration treatment. For CSC treatment, however, we use half that dose. The laser used for PDT is apyrogenic. The total light energy delivered to the area of hyper-permeability detected on ICGA was  $50 \text{ J} \cdot \text{cm}^{-2}$  in all five cases. The spot size covered the area of dilated and congested choroidal vessels, including the foveal region and the area with subretinal pigment epithelium leakage shown by ICGA.<sup>4</sup>

### Case 1

A 53-yr-old man who, 12 yr prior to the current presentation, had been an international airline pilot and had become aware of blurred vision in his right eye. He consulted a neighborhood doctor at that time. He was a nonsmoker. Photocoagulation was performed for CSC treatment. The SRD had initially shown

reattachment, but 7 yr after the onset, he again became aware of blurred vision of his right eye when viewing close objects and impaired night vision (**Fig. 1**).

He was then referred to our hospital. His refraction at the initial visit was +0.50 in the right eye and +0.75 in the left eye. BCVA was 20/20 in the right eye and 20/16 in the left eye. Rephotocoagulation treatment was performed that year. The SRD again showed reattachment, but 3 yr later recurrent SRD was confirmed. A third photocoagulation treatment was performed, but the SRD persisted. At that time, we had just obtained institutional review board approval for using half-dose PDT on CSC patients. Therefore, 10 yr after the onset, half-dose PDT was performed on his right eye and the SRD again showed reattachment within a few weeks. Visual acuity was maintained at 20/12.5 in both eyes for 2 yr. He stopped coming to the hospital, of his own accord, 2 yr after the final PDT.

### Case 2

A 43-yr-old man who, 8 yr prior to the initial visit to our hospital, had been an international airline pilot. He had noticed blurred and distorted vision in his right eye, and consulted a neighborhood doctor. He had a liver disorder and was a nonsmoker. Photocoagulation was performed to treat CSC and SRD reattachment was achieved. However, 2 yr later, recurrence was detected. He elected not to consult a doctor at that time. He was referred to our hospital 8 yr after the onset (**Fig. 2**).

His right visual acuity was 20/40 with a refraction of  $-1.0 - 0.5 \times 010$ . The visual acuity of his left eye was 20/12.5 with a refraction of  $-1.0 \times 080$ . Half-dose PDT was performed for the right eye 6 d after the initial visit to our hospital and SRD remission was confirmed with follow-up examinations over a period of several weeks. His left eye showed indications of CSC 3 yr later. His left visual acuity was 20/12.5 and half-dose PDT was thus performed. Visual acuity of the right eye 5 yr after PDT was 20/40 and refraction was  $-1.00 - 0.50 \times 95$ . Visual acuity of the left eye 2 yr after PDT was maintained at 20/12.5 and refraction was  $+0.75 - 1.25 \times 85$ .

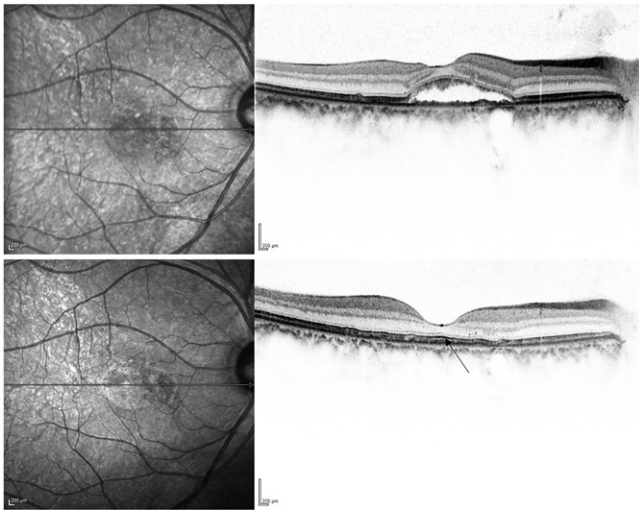
### Case 3

A 43-yr-old man who, 3 yr prior to the current presentation, had become extremely concerned about what he perceived to be blurred vision, photopsia, and a sensation of darkness affecting his right eye. However, he did not notice distortion. He was an international airline pilot and a nonsmoker. He consulted a

**Table I.** Summary of Data from the Five Japanese Commercial Pilots.

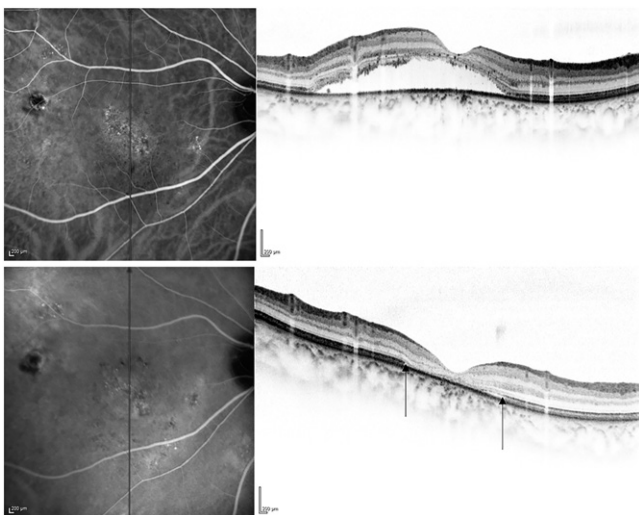
CASE	AGE	EYE (R/L)	LONGEST SRD DURATION (MONTH)	VISUAL ACUITY		TREATMENT	FINAL SRD
				BEFORE PDT	AFTER PDT (CR; YEARS MAINTAINED)		
1	53	R	9	20/20	20/12.5 (2)	PC x 3, PDT x 1	CR
2	43	R	72	20/40	20/40 (5)	PC x 1, PDT x 1	CR
		L	2	20/12.5	20/12.5 (2)	PDT x 1	CR
3	43	R	9	20/12.5	20/12.5 (2)	PDT x 1	CR
4	55	R	6	20/12.5	20/12.5 (2)	PDT x 4	CR
		L	14	20/20	20/12.5 (6)	PDT x 2	CR
5	41	L	5	20/40	20/20 (0.5)	PDT x 1	CR

CR, complete resolution; PC, photocoagulation laser; PDT, photodynamic therapy; SRD, serous retinal detachment.



**Fig. 1.** These images are from Case 1 and are infrared (left) and spectral domain-optical coherence tomography (right) images. The horizontal line is through the fovea on the infrared image. Top: serous retinal detachment (SRD) was detected before treatment. Bottom: The SRD shows reattachment. This image was obtained 2 yr after half-dose photodynamic therapy. Foveal retinal thickness was 150  $\mu\text{m}$ . An ellipsoid zone can be seen in the foveal region (arrow).

neighborhood clinic, but received only a follow-up examination. The severity of the blurred vision had increased 6 mo later, and he was referred to our hospital. BCVA was 20/12.5 in both eyes. Refractions at the initial visit were  $-1.5 \times 175$  and  $+0.75 -1.25 \times 175$ , respectively, in the right and left eyes. Half-dose PDT was performed 3 mo after the patient's first visit to our hospital. The SRD showed reattachment within 2 wk. Visual acuity was maintained at 20/12.5 in both eyes for at least the 2 yr after the PDT.



**Fig. 2.** The images are from Case 2 and are indocyanine green angiography (left) and spectral domain-optical coherence tomography (right) images. The vertical line is through the fovea on the indocyanine green angiography image. Top: serous retinal detachment (SRD) is seen in the right eye at the initial visit. The sensory retina showed thinning at the fovea. Bottom: 3 yr after half-dose photodynamic therapy, the SRD shows reattachment. However, there is a discontinuous ellipsoid zone in the foveal region (arrows). Foveal retinal thickness is only 83  $\mu\text{m}$ .

#### Case 4

A 55-yr-old man who, 8 yr prior to the current presentation, had experienced blurred vision affecting his left eye. He was an international airline pilot and a nonsmoker. The following year, he also experienced blurred vision affecting the right eye and was thus referred to our hospital. At that time, SRD was confirmed in both eyes. BCVA was 20/12.5 in the right eye and 20/20 in the left eye. Refractions at the initial visit were  $-1.75 -0.25 \times 050$  and  $-1.5 -0.25 \times 025$ , respectively, in the right and left eyes. The first half-dose PDT on the left eye was performed 3 mo after the initial visit. SRD disappeared within a few weeks after treatment and spontaneous remission in the right eye was confirmed 3 mo after the left eye had been treated. Recurrence was documented in the left eye 9 mo after half-dose PDT, necessitating a second treatment on his left eye. The SRD showed reattachment within a few weeks. Visual acuity of the left eye was maintained 6 yr after the left PDT at 20/12.5 and refraction was  $-1.75 -0.75 \times 90$ .

His right eye also showed recurrence 4 yr after the onset and the first half-dose PDT was performed on the right eye. He was reinstated as a pilot within 1 mo. BCVA was 20/12.5 in both eyes at that time. However, mild right SRD persisted and he received a second treatment 4 mo after the first. Yet persistent right SRD necessitated a third treatment 3 mo after the second. Despite the third treatment, right SRD continued to persist. Therefore, a fourth treatment was performed 6 mo after the third. The SRD reattached within a few weeks. Visual acuity has since been maintained at 20/12.5 and refraction was  $-2.00 -0.75 \times 75$  at the last examination. There has been no recurrence for 2 yr to date since the fourth treatment for the right eye.

#### Case 5

A 41-yr-old man, who was an international airline pilot and a nonsmoker, noticed a yellow ring over his left eye 4.5 yr prior to the current presentation. Subsequently, he experienced several remissions and exacerbations of this ring, and consulted a neighborhood clinic. At that time, BCVA was maintained at 20/20, though he sensed a gradual vision loss in the left eye. His symptoms had clearly worsened 4 yr after the onset and he was aware of blurred vision affecting both his far and his near vision, and he also complained of distortion. Therefore, he was referred to our hospital. At the initial visit, his left BCVA was 20/40, right 20/12.5, with respective right and left eye refractions of  $+0.5 -0.25 \times 020$  and  $+1.0 -0.25 \times 010$ . Half-dose PDT was promptly performed and the SRD showed reattachment within 3 wk. He was able to renew his pilot's license. BCVA increased to 20/20 in his left eye and has been maintained for 6 mo to date.

#### DISCUSSION

In CSC patients, measurements of blood pressure and heart rate variability indicate significant sympathetic over-activation and decreased parasympathetic activity.<sup>12</sup> A recent case report

described hypobaric chamber exposure as a possible cause, suggesting that altitude decompression sickness might be one of the causes of CSC development in pilots.<sup>6</sup> Recently, the thick choroid phenomenon was reported to occur during parabolic flight.<sup>1</sup> The choroid is thicker in CSC than in healthy eyes. Choroidal vascular hyper-permeability is thought to raise hydrostatic pressure in the choroid and to thereby increase choroidal thickness.<sup>7</sup> Sleeping disorders are also among the risk factors for CSC.<sup>9</sup> In this study, based on all of these active pilots having been engaged in long-haul operations, we can reasonably speculate that these pilots were working under very stressful circumstances and had irregular sleep patterns. These various factors might contribute to CSC development in pilots.

As in our Cases 1 and 2, multiple focal laser photocoagulation treatments might cause focal scotoma. On the other hand, the PDT laser is apyrogenic, such that it cannot cause scotoma. However, patients undergoing PDT must be careful of sunlight exposure for 48 h, the time needed for the verteporfin, which is a photosensitizer, to be excreted from the body. Moreover, patients who have compromised liver functions, such as our Case 2, need to be especially careful, allowing 5 d for verteporfin to be excreted from the body. Therefore, when selecting CSC treatment, patients must be mindful of the advantages and disadvantages. Even in cases with SRD development, spontaneous SRD remission occasionally occurs and photoreceptor cells are maintained. However, the longer the SRD persists, the poorer the visual acuity outcome.<sup>10</sup> If SRD persists for several years, it can cause gradual vision loss and retinal thinning as in our Case 2. Therefore, if pilots notice any visual disturbance, they should immediately consult an ophthalmologist. Case 4 required four treatments in total for the right eye, but visual acuity was well maintained. Patients may experience CSC recurrences, such that retreatment in the early stage remains important. If patients experience a sensation of darkness in the visual field due to serous retinal detachment, night vision will deteriorate. Even when visual acuity improves or is at least maintained after PDT, patients often complain of slight distortion, decreased night vision, and/or slight color changes. Therefore, even after resolution, metamorphopsia examination, color perception testing, or determination of subjective vision symptoms appears to be needed. It must be kept in mind that these issues can affect flight status and/or flight performance.

The mean annual age-adjusted incidences of CSC per 100,000 are reportedly 9.9 for men and 1.7 for women.<sup>8</sup> The total number of CSC cases among pilots is unknown, but we advocate regular fundus examinations for commercial airline pilots and early treatment, i.e., before visual acuity decreases.

Half-dose PDT is reportedly an effective method in that reduction or disappearance of SRD is achieved within a few weeks.<sup>3</sup> In this study, none of our patients developed systemic

complications associated with verteporfin nor were any severe visual reductions experienced after treatment, results consistent with those of a previous report.<sup>3</sup> The cost of treating CSC with PDT is very high in Japan due to its off-label use. However, for pilots assigned important duties, including aircraft operation, early treatment before visual acuity loss is highly recommended.

## ACKNOWLEDGMENTS

This work was supported by Nihon University Hospital.

*Authors and affiliations:* Ari Shinojima, M.D., Ph.D., Ryusaburo Mori, M.D., Ph.D., and Mitsuko Yuzawa, M.D., Ph.D., Department of Visual Science, Division of Ophthalmology, Nihon University Hospital, Nihon University School of Medicine, Tokyo, Japan; and Kyoko Fujita, M.D., Ph.D., Department of Ophthalmology, Kansai Medical University Hospital, Hirakata City, Japan.

## REFERENCES

1. Anderson AP, Swan JG, Phillips SD, Knaus DA, Kattamis NT, et al. Acute effects of changes to the gravitational vector on the eye. *J Appl Physiol* (1985). 2016; 120(8):939–946.
2. Behnia M, Khazakhoob M, Aliakbari S, Abadi AE, Hashemi H, Pourvahidi P. Improvement in visual acuity and contrast sensitivity in patients with central serous chorioretinopathy after macular subthreshold laser therapy. *Retina*. 2013; 33(2):324–328.
3. Fujita K, Imamura Y, Shinoda K, Matsumoto CS, Mizutani Y, et al. One-year outcomes with half-dose verteporfin photodynamic therapy for chronic central serous chorioretinopathy. *Ophthalmology*. 2015; 122(3):555–561.
4. Fujita K, Yuzawa M, Mori R. Retinal sensitivity after photodynamic therapy with half-dose verteporfin for chronic central serous chorioretinopathy: short-term results. *Retina*. 2011; 31(4):772–778.
5. Gass JD. Pathogenesis of disciform detachment of the neuroepithelium. *Am J Ophthalmol*. 1967; 63(3, Suppl.):1–139.
6. Ide WW. Central serous chorioretinopathy following hypobaric chamber exposure. *Aviat Space Environ Med*. 2014; 85(10):1053–1055.
7. Jirarattanasopa P, Ooto S, Tsujikawa A, Yamashiro K, Hangai M, et al. Assessment of macular choroidal thickness by optical coherence tomography and angiographic changes in central serous chorioretinopathy. *Ophthalmology*. 2012; 119(8):1666–1678.
8. Kitzmann AS, Pulido JS, Diehl NN, Hodge DO, Burke JP. The incidence of central serous chorioretinopathy in Olmsted County, Minnesota, 1980–2002. *Ophthalmology*. 2008; 115(1):169–173.
9. Liu B, Deng T, Zhang J. Risk factors for central serous chorioretinopathy: A systematic review and meta-analysis. *Retina*. 2016; 36(1):9–19.
10. Liu DT, Fok AC, Chan W, Lai TY, Lam DS. Central serous chorioretinopathy. In: Ryan SJ, editor. *Retina*, 5th ed. Philadelphia: Elsevier/Saunders; 2013:1291–1305.
11. Piccolino FC, de la Longrais RR, Ravera G, Eandi CM, Ventre L, et al. The foveal photoreceptor layer and visual acuity loss in central serous chorioretinopathy. *Am J Ophthalmol*. 2005; 139(1):87–99.
12. Tewari HK, Gadia R, Kumar D, Venkatesh P, Garg SP. Sympathetic-parasympathetic activity and reactivity in central serous chorioretinopathy: a case-control study. *Invest Ophthalmol Vis Sci*. 2006; 47(8):3474–3478.